

## Three-dimensional Echocardiography for Percutaneous Occlusion of Patent Foramen Ovale

Robinson Poffo, Paola Keese Montanhesi, Renato Bastos Pope, Alisson Parrilha Toschi, Marcelo Campos Vieira

Hospital Israelita Albert Einstein – São Paulo, SP – Brazil

Female patient, 31 years old, with a history of ischemic stroke 7 years before, was referred for treatment of Patent Foramen Ovale (PFO). She only had a complaint of migraine with aura, with no focal neurological abnormalities.

On July 2, 2015, she was submitted to an uneventful percutaneous PFO occlusion using a Cardia Intrasept™ prosthesis (CARDIA, Inc., Burnsville, MN, USA). Intraoperative three-dimensional transesophageal echocardiography confirmed correct prosthesis positioning and absence of residual shunt through the bubble test. Current guidelines of the two most important international societies of echocardiography, the European Association of Cardiovascular Imaging and the American Society of Echocardiography, determine that the three-dimensional echocardiography is the echocardiographic modality of choice for monitoring, following and guiding percutaneous procedures performed in hemodynamics and hybrid rooms, as in this case.<sup>1</sup>

The patient was discharged on the first postoperative day. After 30 days, adequate placement of the device

was confirmed with PFO occlusion through transthoracic echocardiography. The patient remains in outpatient care, with migraine improvement.

### Author contributions

Conception and design of the research and Writing of the manuscript: Poffo R; Acquisition of data: Montanhesi PK, Pope RB, Toschi AP, Vieira MC; Analysis and interpretation of the data: Poffo R, Montanhesi PK; Critical revision of the manuscript for intellectual content: Poffo R, Montanhesi PK, Vieira MC.

### Potential Conflict of Interest

No potential conflict of interest relevant to this article was reported.

### Sources of Funding

There were no external funding sources for this study.

### Study Association

This study is not associated with any thesis or dissertation work.

### Keywords

Foramen Ovale, Patent / surgery; Echocardiography, Three-Dimensional; Minimally Invasive Surgical Procedures.

#### Mailing Address: Paola Keese Montanhesi •

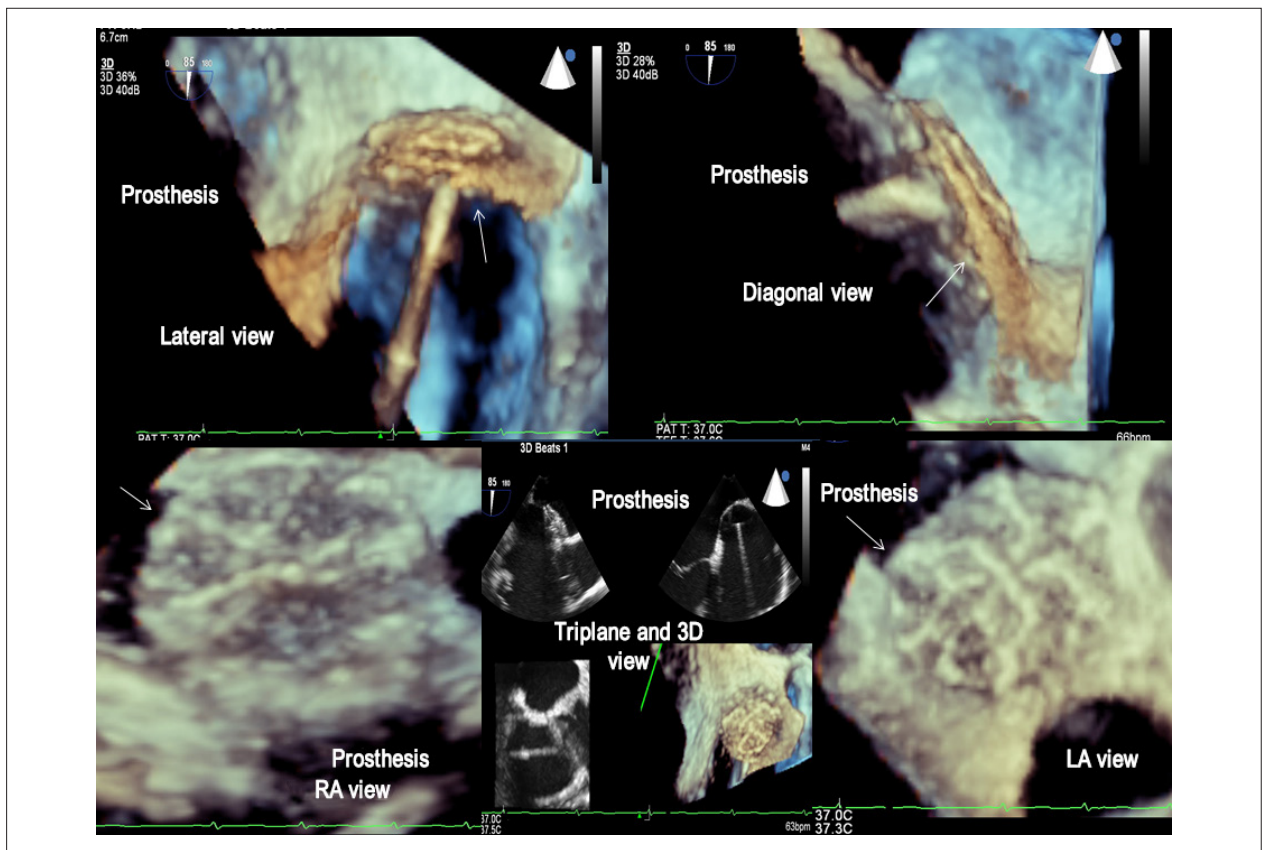
Hospital Israelita Albert Einstein. Av. Albert Einstein, 627/701 Bloco A1 -

Sala 421, 4º andar. Postal Code 05652-901, São Paulo, SP – Brazil

E-mail: paolakeese@gmail.com, paola.keese@einstein.br

Manuscript received October 21, 2015; revised manuscript November 03, 2015; accepted November 03, 2015.

DOI: 10.5935/abc.20160036



**Figure 1** – Three-dimensional transesophageal echocardiography image in multiple planes (from the left atrium, the right atrium, from the lateral, diagonal and triplane views) of the Cardia Intrasept™ prosthesis (arrow) well positioned in the atrial septum in a patient with patent foramen ovale. RA: right atrium; LA: left atrium.

## Reference

1. Lang R M, Badano L P, Tsang W T, Adams DH, Agricola E, Buck T, et al; American Society of Echocardiography; European Association of Echocardiography. EAE/ASE recommendations for image acquisition and display using three-dimensional echocardiography. *J Am Soc Echocardiogr.* 2012;25(1):3-46.